



PATIENT

Riley Robbins

SPECIES

Feline

BREED

DSH

SEX

Male Neutered

AGE

13 years

WEIGHT

13.5lbs

INTERPRETED BY

Maggie Machen Lamy,
DVM, DACVIM
(Cardiology)

IMAGING PERFORMED BY

Sands Hill Mobile
Veterinary Ultrasound

HOSPITAL NAME

Surf City Animal
Hospital

REFERRING VET

Dr. Wick

INVOICE

26259

DATE

8/9/22

PRESENTING CLINICAL SIGNS

History: Progressive grade 4/6 murmur. Asymptomatic.

ECHOCARDIOGRAM FINDINGS

2D, m-mode, color flow and doppler imaging is available. The left ventricular wall is largely normal in dimension. Region of dropout in the interventricular septum just below the aortic valve; however, no flow is seen across on color flow or Spectral doppler. There is a diffusely hyperechoic endocardium consistent with fibrosis and remodeling. The endocardium also appears remodeled. The MV appears normal. A mildly elevated LVOT velocity is noted on color flow. Trace MR, likely secondary to abnormal valve motion. The left atrium is normal in size. The right atrium is normal. The right ventricle appears normal. Blood flow through the RVOT is normal in velocity. Trace TR. There is no pleural or pericardial effusion seen. There are no obvious cardiac tumors.

CARDIAC CHART

FELINE CARDIAC PARAMETERS	BODY WEIGHT (kg)	HR (BPM)	IVSd (cm) (Moise, Pipers)	LVIDd (cm) (Moise, Pipers)	LWVd (cm) (Moise, Pipers)	FS (%)	EF (%)
NORMAL PARAMETER	-----	150-240	0.35-0.55	<2 (mean 1.5)	3.5-0.55	35-67	80-100
PATIENT	6.1	NM	0.48	1.48	0.48	6492	
FELINE CARDIAC PARAMETERS	LA/AO (Boon)	LA/AO HEART BASE (Swe) (Abbott)	LA 2D short axis Base view (cm) (Abbott)		LVOT VEL (m/s)	RVOT VEL (m/s)	E max (m/s)
NORMAL	<1.5	<1.3	<1.2		<1.6	<1.3	<0.9
PATIENT	NM	1.2	1.2		1.3	1.2	NM

**Note: All measurements based upon multi-modal images and methods. An average value is reported.*
Adapted from June Boon, Veterinary Echocardiography, 1998
Abbott J & MacLean H JVIM 2006;20: 111-119, Moise et al. Am J Vet Res 47:1476, 1986. Pipers et al. Am J Vet Res 40:882, 1979.

INTERPRETATION OF THE FINDINGS & FURTHER RECOMMENDATIONS

Overtly normal cardiac structure and function. The murmur is likely due to an intermittent LVOT obstruction, secondary to abnormal valve movement at elevated heart rates. There is also mild remodeling and fibrosis of the left ventricular wall. These changes may be indicative of early cardiac disease (HOCM) or may simply represent a normal variant. Serial echocardiography will be necessary to determine progression and clinical relevance of both findings. No additional issues are identified.

In patients with persistent LVOT obstruction and an elevated pressure gradient, a beta blocker is often prescribed to lower heart rate and decrease the gradient. In this patient with a mild obstruction and borderline normal LA/LV dimensions, no medications are clearly indicated.

From a structural standpoint, anesthetic risk is currently low. Avoid heart rate stimulating drugs (atropine, glycopyrrolate) unless clinically necessary. Avoid vasodilators such as acepromazine as this can worsen obstruction. Judicious IV fluid rates are recommended to avoid fluid overload in this patient with diastolic dysfunction.



PATIENT

Riley Robbins

A recheck echocardiogram is recommended in 6-12 months, sooner if any clinical signs arise.

IMAGES

SPECIES

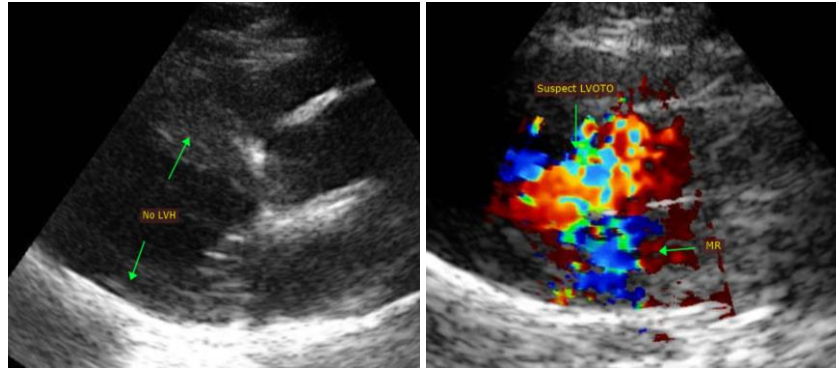
Feline

BREED

DSH

SEX

Male Neutered



AGE

13 years

The information and recommendations provided are based on the images presented by the referring veterinarian. No evaluation can be communicated regarding pathology that was not visible in the image/video clips provided.

WEIGHT

13.5lbs

Thank you for this referral. This report was generated using transcription software, and minor dictation errors may be present. If the clinical or image interpretation does not parallel your findings or if I can be of any further assistance, please contact me.

INTERPRETED BY

Maggie Machen Lamy,
DVM, DACVIM
(Cardiology)

Maggie Machen Lamy, DVM

Diplomate of the American College of Veterinary Internal Medicine (Cardiology)

info@sonopath.com

IMAGING PERFORMED BY

Sands Hill Mobile
Veterinary Ultrasound

HOSPITAL NAME

Surf City Animal
Hospital

REFERRING VET

Dr. Wick

INVOICE

26259

DATE

8/9/22